

Narrative Review Article: Breast Cancer Surgery | Guideline for Increase Survival Rate: Narrative Review

Seyed Vahid Seyed Hosseini

General Surgeon, Sina Hospital, Tabriz University of Medical science, Tabriz, Iran. (ORCID: 0009-0002-1365-3038)

Use your device to scan and read the article online



Citation S.V. Seyed Hosseini, **Breast Cancer Surgery Guideline for Increase Survival Rate: Narrative Review**, *EJCMPR* . 2024; 3(2): Article in Press



<https://doi.org/EJCMPR/20231220>

Article info:

Received: 16 September 2023

Accepted: 17 December 2023

Available Online:

ID: EJCMPR-2312-1130

Checked for Plagiarism: Yes

Peer Reviewers Approved by:

Dr. Frank Rebut

Editor who Approved Publication:

Dr. Frank Rebut

Keywords:

Breast Cancer, Surgery, Guideline, Survival rate

ABSTRACT

Breast cancer surgery plays a critical role in the management of breast cancer and is aimed at improving survival rates. Evidence-based guidelines have been developed to provide standardized recommendations for surgical interventions in breast cancer patients. These guidelines encompass various aspects of breast cancer surgery, including the selection of appropriate surgical procedures, achievement of clear surgical margins, timing of surgery, and the importance of multidisciplinary collaboration. The guidelines emphasize the importance of achieving clear surgical margins, which is associated with a decreased risk of local recurrence and improved survival rates. Breast-conserving surgery, such as lumpectomy, is recommended in eligible patients to achieve tumor removal while preserving the breast. Mastectomy, the complete removal of breast tissue, may be necessary in certain cases, and the guidelines provide recommendations for patient selection and optimal timing. Sentinel lymph node biopsy is an integral part of breast cancer surgery for accurate staging and determining appropriate adjuvant therapies. The guidelines highlight the importance of multidisciplinary collaboration to ensure comprehensive evaluation, treatment planning, and follow-up care. Adherence to these guidelines, along with the integration of systemic therapies, such as chemotherapy and hormonal therapy, has shown to improve survival rates in breast cancer patients. Ongoing research and advancements in surgical techniques and molecular profiling continue to refine these guidelines, further enhancing the effectiveness of breast cancer surgery and overall patient survival rates. By following these evidence-based guidelines, healthcare professionals can optimize patient care and contribute to increased survival rates in breast cancer patients.

Introduction

Gastric Breast cancer is a significant public health concern, affecting millions of women worldwide [1-3]. Surgical intervention plays a crucial role in the management of breast cancer,

aiming to remove the tumor and prevent its spread to improve patient outcomes and increase survival rates [4-6]. Over the years, extensive research and clinical experience have led to the development of evidence-based guidelines for breast cancer surgery. These guidelines provide healthcare professionals

*Corresponding Author: Seyed Vahid Seyed Hosseini (seyedhosseiniseyedvahid@gmail.com)

with standardized recommendations for surgical approaches [7-9], techniques, and adjuvant therapies to optimize patient care and improve survival rates.

The primary goals of breast cancer surgery are to achieve complete tumor removal, evaluate nodal involvement [10-12], and perform appropriate axillary staging. The choice of surgical procedure depends on various factors, including tumor characteristics, patient preferences [11-13], and the expertise of the surgical team. The two main surgical approaches for breast cancer are breast-conserving surgery (BCS) and mastectomy [14-16].

Breast-conserving surgery, also known as lumpectomy or partial mastectomy, involves the removal of the tumor along with a rim of healthy tissue surrounding it. This approach is typically followed by adjuvant radiation therapy to ensure local control [17-19]. Breast-conserving surgery is considered a standard option for early-stage breast cancer when the tumor size allows for adequate resection with clear margins. Several clinical trials have demonstrated equivalent survival rates between BCS and mastectomy, making it an attractive option for many patients seeking breast preservation [20].

Mastectomy involves the complete removal of the breast tissue, and it can be performed as a total mastectomy or modified radical mastectomy [21-23]. Total mastectomy removes the entire breast tissue, while modified radical mastectomy also includes axillary lymph node dissection. Mastectomy is typically recommended for patients with larger tumors, multifocal disease, extensive ductal carcinoma in situ (DCIS) [24-26], or when breast-conserving surgery is contraindicated. In recent years, the use of skin-sparing and nipple-sparing mastectomy techniques has gained popularity, providing better cosmetic outcomes and improved psychological well-being for patients.

Axillary lymph node status is a crucial factor in breast cancer staging and treatment planning. Sentinel lymph node biopsy (SLNB) has become the standard approach for axillary staging in clinically node-negative patients [27-29]. SLNB involves the identification and removal of the first lymph node(s) to which the tumor is most likely to spread, known as the sentinel lymph node(s) [30-32]. This procedure reduces the risk of complications associated with extensive axillary lymph node dissection while maintaining accurate staging information. However [33-35], in cases where the sentinel lymph node is found to be positive for metastasis, additional axillary lymph node dissection may be recommended [36-38].

Adjuvant therapies, such as radiation therapy, chemotherapy, hormonal therapy, and targeted therapy, are essential components of breast cancer treatment and contribute to improved survival rates [39-41]. The decision to administer adjuvant therapies is based on various factors, including tumor characteristics, nodal involvement, and the presence of hormone receptors or specific molecular markers. Multidisciplinary collaboration between surgeons, oncologists, pathologists, and radiologists is crucial for determining the most appropriate adjuvant therapy regimen to optimize patient outcomes [42-44].

In recent years, there have been significant advancements in breast reconstruction techniques following mastectomy, offering women the option to restore their breast shape and improve body image. Immediate breast reconstruction at the time of mastectomy or delayed reconstruction performed at a later stage can be considered based on patient preferences, tumor characteristics, and individual circumstances [45-47]. Breast reconstruction has been shown to have positive psychological and emotional impacts, enhancing overall quality of life for breast cancer survivors.

In conclusion [48], breast cancer surgery guidelines encompass a wide array of recommendations for the management of breast cancer, aiming to achieve complete tumor removal, evaluate nodal involvement, and optimize adjuvant therapies to increase survival rates. The choice of surgical approach, whether breast-conserving surgery or mastectomy, depends on individual patient factors and tumor characteristics [41]. Axillary lymph node staging through sentinel lymph node biopsy plays a crucial role in determining the extent of axillary surgery [2].

Adjuvant therapies, including radiation therapy, chemotherapy, hormonal therapy, and targeted therapy, are integral components of breast cancer treatment. Multidisciplinary collaboration and patient-centered decision-making are essential to ensure the best possible outcomes for breast cancer patients. Future research and advancements in surgical techniques, adjuvant therapies, and breast reconstruction will continue to refine breast cancer surgery guidelines and further improve survival rates [48].

Breast-conserving surgery

Breast cancer is a prevalent disease affecting women worldwide, and its management requires a comprehensive approach to achieve the best possible outcomes [5]. Breast-conserving surgery (BCS), also known as lumpectomy or partial mastectomy, has become a well-established treatment option for early-stage breast cancer. This surgical approach aims to remove the tumor while preserving the breast, offering both oncological control and improved cosmetic outcomes. In recent years, evidence-based guidelines for breast-conserving surgery have been developed to guide healthcare professionals in optimizing patient care and increasing survival rates (fig 1).

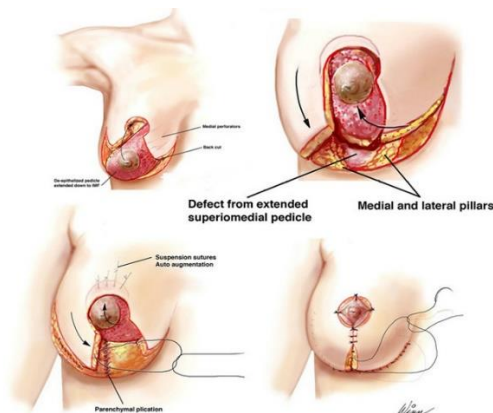


Figure 1. Breast-conserving surgery Method

Breast-conserving surgery involves the removal of the tumor along with a margin of healthy tissue surrounding it. The primary goal is to achieve complete tumor excision with negative surgical margins, ensuring that no cancerous cells are left behind. This is crucial for reducing the risk of local recurrence and improving overall survival.

The decision to perform breast-conserving surgery depends on several factors, including tumor characteristics, patient preferences, and the expertise of the surgical team. It is typically considered a suitable option for early-stage breast cancer when the tumor size allows for adequate resection while maintaining good cosmetic results. The selection process involves careful evaluation of the tumor's size, location, and relationship to the surrounding breast tissue, as well as the patient's breast size and shape. Additionally, the presence of multiple tumors, extensive ductal carcinoma in situ (DCIS), or certain tumor characteristics may influence the decision to pursue breast-conserving surgery.

To ensure the success of breast-conserving surgery, accurate preoperative imaging and meticulous surgical planning are essential. Preoperative imaging, such as mammography, ultrasound, and magnetic resonance imaging (MRI), helps determine the extent and location of the tumor, assess breast density, and identify any additional lesions. This information guides

the surgeon in planning the surgical approach and determining the appropriate margin width. Achieving negative surgical margins is a critical factor in the success of breast-conserving surgery. Guidelines recommend a margin width of at least 2 mm or no ink on tumor for invasive cancer and 2 mm for DCIS. If the surgical margins are found to be positive for tumor cells, re-excision or mastectomy may be considered to ensure complete tumor removal. The use of intraoperative techniques, such as specimen radiography and frozen section analysis, can aid in assessing margin status and guide the decision for further surgical intervention [7].

Following breast-conserving surgery, adjuvant therapies are typically recommended to reduce the risk of local recurrence and improve overall survival. These may include radiation therapy, chemotherapy, hormonal therapy, or targeted therapy, depending on the tumor characteristics and patient-specific factors. Radiation therapy is an integral part of breast-conserving surgery and has been shown to significantly reduce the risk of local recurrence. It is typically delivered to the remaining breast tissue after surgery and may also involve treatment of the regional lymph nodes.

The selection of adjuvant therapies is based on a multidisciplinary approach, involving collaboration between surgeons, oncologists, pathologists, and radiologists. These experts evaluate the tumor's biological characteristics, such as hormone receptor status, human epidermal growth factor receptor 2 (HER2) status, and genomic profiling, to guide the choice of appropriate systemic therapies.

Breast-conserving surgery offers several advantages to patients, including the preservation of the breast, improved body image, and psychological well-being. It is associated with lower morbidity and a faster recovery compared to more extensive surgical procedures, such as mastectomy. Moreover, breast-conserving surgery has been shown to

yield equivalent survival rates compared to mastectomy, making it an attractive option for many women.

In conclusion, breast-conserving surgery guidelines provide evidence-based recommendations for the management of early-stage breast cancer, aiming to increase survival rates while preserving the breast. Accurate tumor assessment, meticulous surgical planning, and achieving negative surgical margins are essential components of successful breast-conserving surgery. Collaboration among healthcare professionals is crucial in determining the appropriate adjuvant therapies based on tumor characteristics and patient-specific factors. Breast-conserving surgery offers several advantages, improving both oncological outcomes and patients' quality of life. Ongoing research and advancements in imaging techniques, surgical approaches, and adjuvant therapies will further refine the guidelines and contribute to better outcomes for breast cancer patients undergoing breast-conserving surgery [12].

Mastectomy

Breast cancer is a complex and multifaceted disease that affects millions of women worldwide. The management of breast cancer requires a comprehensive approach, and surgery plays a crucial role in achieving optimal outcomes. Mastectomy, the surgical removal of the breast tissue, has been a cornerstone of breast cancer treatment for many years. Evidence-based guidelines have been developed to provide healthcare professionals with standardized recommendations for performing mastectomy and optimizing patient care to increase survival rates.

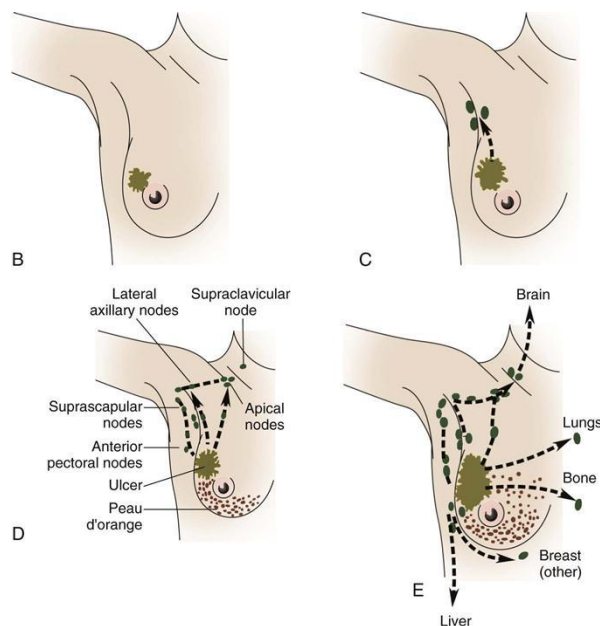


Figure 2. Mastectomy Methods

Mastectomy is recommended for various indications, including large tumors, multifocal disease, extensive ductal carcinoma in situ (DCIS), or when breast-conserving surgery is contraindicated. It involves the complete removal of the breast tissue and can be performed as a total mastectomy or modified radical mastectomy, depending on the extent of lymph node dissection. The selection of the appropriate surgical approach depends on tumor characteristics, patient preferences, and the expertise of the surgical team.

The primary goal of mastectomy is to achieve complete tumor removal while minimizing the risk of local recurrence. Achieving negative surgical margins, meaning no cancer cells are present at the edges of the removed tissue, is essential for reducing the risk of local recurrence and improving survival rates. Intraoperative techniques, such as frozen section analysis and specimen radiography, can assist surgeons in assessing margin status and guide the decision for further tissue removal if necessary.

The decision to perform immediate breast reconstruction at the time of mastectomy or delayed reconstruction at a later stage is an

important consideration in the surgical plan. Breast reconstruction techniques have advanced significantly in recent years, offering women the option to restore their breast shape and improve body image. Immediate breast reconstruction has been shown to have positive psychological and emotional impacts, leading to improved quality of life for breast cancer survivors.

Axillary lymph node status is a critical factor in breast cancer staging and treatment planning. The presence of lymph node involvement affects prognosis and guides the selection of adjuvant therapies. In cases where lymph node involvement is suspected, sentinel lymph node biopsy (SLNB) has become the standard approach for axillary staging. SLNB involves the identification and removal of the first lymph node(s) to which the tumor is most likely to spread, known as the sentinel lymph node(s). If sentinel lymph nodes are found to be positive for metastasis, additional axillary lymph node dissection may be recommended.

Adjuvant therapies, such as radiation therapy, chemotherapy, hormonal therapy, and targeted therapy, play a crucial role in improving survival rates and reducing the risk of disease recurrence. The decision to administer adjuvant therapies is based on various factors, including tumor characteristics, nodal involvement, and the presence of hormone receptors or specific molecular markers. Multidisciplinary collaboration among surgeons, oncologists, pathologists, and radiologists is vital in determining the most appropriate adjuvant therapy regimen to optimize patient outcomes. Mastectomy guidelines also emphasize the importance of postoperative surveillance and follow-up. Regular monitoring through physical examinations, imaging studies, and tumor marker assessments helps detect any signs of recurrence or metastasis at an early stage, allowing for timely intervention and improved survival rates.

It is worth noting that mastectomy has evolved over time, with advances in surgical techniques and approaches aimed at optimizing outcomes. The advent of skin-sparing and nipple-sparing mastectomy techniques has gained popularity, as they preserve more breast skin and maintain the natural appearance of the breast. These techniques offer improved cosmetic outcomes and psychological well-being for patients without compromising oncological control.

In conclusion, mastectomy guidelines provide evidence-based recommendations for the surgical management of breast cancer, with the ultimate goal of increasing survival rates. Mastectomy remains a crucial treatment option for patients with breast cancer, offering complete tumor removal and the potential for breast reconstruction. Accurate tumor assessment, achieving negative surgical margins, and appropriate axillary staging are essential components of successful mastectomy. Collaboration among healthcare professionals is vital in determining the most appropriate adjuvant therapies based on tumor characteristics and patient-specific factors. Ongoing research and advancements in surgical techniques, adjuvant therapies, and postoperative surveillance will continue to refine the guidelines and contribute to better outcomes for breast cancer patients undergoing mastectomy.

Axillary lymph node

Breast cancer is a complex disease that requires a comprehensive approach to optimize patient outcomes. One crucial aspect of breast cancer management is the evaluation of axillary lymph node status. The presence or absence of lymph node involvement significantly impacts prognosis, treatment planning, and the overall survival rate. Evidence-based guidelines have been developed to guide healthcare professionals in assessing axillary lymph nodes

accurately and making informed decisions to increase survival rates in breast cancer patients. Axillary lymph nodes are the first regional lymph nodes to which breast cancer cells are likely to spread. The evaluation of axillary lymph node status provides crucial information about the extent of disease and helps guide treatment decisions. Traditionally, axillary lymph node dissection (ALND) was the standard procedure for assessing the lymph nodes' involvement in breast cancer. However, advances in surgical techniques and a better understanding of the disease have led to the development of sentinel lymph node biopsy (SLNB) as a less invasive alternative (fig 3).

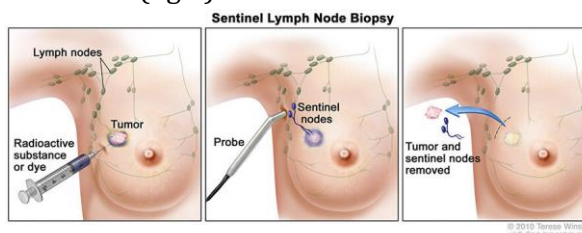


Figure 3. Axillary lymph nodes

Sentinel lymph node biopsy involves the identification and removal of the first lymph node(s) to which cancer cells are most likely to spread, known as the sentinel lymph node(s). This approach allows for accurate staging of the axilla while minimizing the morbidity associated with complete axillary lymph node dissection. The sentinel lymph node(s) are identified by injecting a tracer dye or radioisotope near the tumor, which then travels to the sentinel lymph node(s). Surgeons can visualize and remove the stained or radioactive lymph node(s) for further examination.

Accurate identification and evaluation of sentinel lymph nodes are crucial for determining the extent of axillary involvement and guiding subsequent treatment decisions. Pathological examination of the sentinel lymph nodes provides essential information about the presence of metastasis and helps assess the need for further axillary lymph node dissection or

adjuvant therapies. In cases where sentinel lymph nodes are found to be positive for cancer cells, complete axillary lymph node dissection may be considered to remove additional lymph nodes and reduce the risk of disease recurrence. Axillary lymph node guidelines emphasize the importance of accurately staging the axilla to inform treatment decisions and improve survival rates in breast cancer patients. These guidelines provide recommendations on the optimal techniques for sentinel lymph node identification, such as the use of dual-tracer techniques combining dye and radioisotope, which have been shown to increase the sensitivity and accuracy of sentinel lymph node detection.

In addition to SLNB, advancements in molecular profiling and genetic testing have further refined the evaluation of axillary lymph node status. Molecular profiling techniques, such as gene expression profiling and next-generation sequencing, provide valuable information about the tumor's biological characteristics and can help predict the likelihood of lymph node involvement. These tools aid in risk stratification, allowing for tailored treatment plans based on individual patient needs.

The results of axillary lymph node evaluation have a significant impact on treatment planning and the selection of adjuvant therapies. Adjuvant therapies, including radiation therapy, chemotherapy, hormonal therapy, and targeted therapy, are essential for reducing the risk of disease recurrence and improving survival rates. The presence of lymph node involvement influences the decision to administer these therapies and helps guide their duration and intensity.

Multidisciplinary collaboration among surgeons, oncologists, pathologists, and radiologists is critical in accurately assessing axillary lymph nodes and determining the most appropriate treatment strategies. Regular tumor board meetings and discussions ensure that the

expertise of different specialists is utilized to make informed decisions based on the latest evidence and guidelines.

Ongoing research and advancements in axillary lymph node evaluation continue to refine the guidelines and improve patient outcomes. Innovations in imaging techniques, such as molecular imaging and functional imaging, hold promise for further enhancing the accuracy of sentinel lymph node detection and reducing false-negative rates. Additionally, the incorporation of artificial intelligence and machine learning algorithms into lymph node evaluation may help improve accuracy and streamline the decision-making process.

In conclusion, axillary lymph node guidelines play a vital role in the management of breast cancer, aiming to increase survival rates by accurately evaluating lymph node involvement. Sentinel lymph node biopsy has emerged as a less invasive alternative to traditional axillary lymph node dissection, providing valuable information for treatment planning while minimizing morbidity. Accurate identification and evaluation of sentinel lymph nodes guide subsequent treatment decisions, including the use of adjuvant therapies. Multidisciplinary collaboration and ongoing research contribute to the refinement of guidelines and the continuous improvement of patient outcomes. The integration of novel imaging techniques and molecular profiling holds promise for further enhancing axillary lymph node evaluation and optimizing treatment strategies for breast cancer patients.

Breast reconstruction

Breast cancer is a complex disease that affects millions of women worldwide. The management of breast cancer requires a comprehensive approach, and breast reconstruction plays a vital role in restoring a woman's body image and quality of life after mastectomy or breast-conserving surgery. Evidence-based guidelines

have been developed to provide healthcare professionals with standardized recommendations for performing breast reconstruction and optimizing patient care to increase survival rates.

Breast reconstruction is a surgical procedure that aims to restore the shape, symmetry, and aesthetics of the breast after mastectomy or lumpectomy. It can be performed immediately at the time of mastectomy or as a delayed procedure after completing other adjuvant therapies. Breast reconstruction options include implant-based reconstruction, autologous tissue reconstruction using the patient's own tissue, or a combination of both techniques (fig 4).

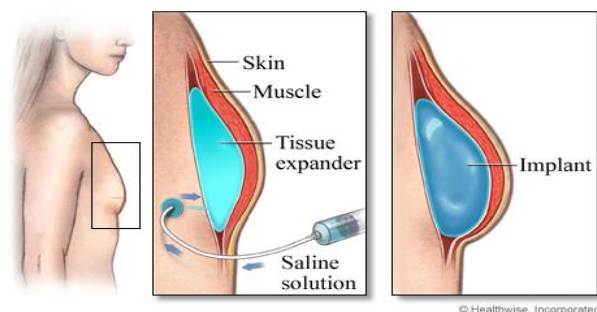


Figure 4. Breast reconstruction

The primary goal of breast reconstruction is to improve the psychological well-being and quality of life of breast cancer survivors. Reconstruction can help address the physical and emotional impact of breast loss, allowing women to regain confidence in their appearance and restore their sense of femininity. Numerous studies have shown that breast reconstruction positively impacts a woman's self-esteem, body image, and overall quality of life.

Guidelines for breast reconstruction emphasize the importance of patient-centered care and shared decision-making. The choice of reconstruction technique depends on various factors, including the patient's preferences, body habitus, previous surgeries, comorbidities, and the availability of donor sites for autologous tissue reconstruction. The surgeon's expertise and skill level in performing different

reconstruction techniques also play a significant role in the decision-making process.

Implant-based reconstruction involves the use of silicone or saline implants to recreate the breast mound. This technique is generally less invasive and has a shorter recovery time compared to autologous tissue reconstruction. However, it may require multiple surgeries over time for implant adjustments or revisions. The guidelines provide recommendations for implant selection, appropriate sizing, and the optimal timing for implant-based reconstruction.

Autologous tissue reconstruction, also known as flap reconstruction, utilizes the patient's own tissue, typically from the abdomen (transverse rectus abdominis muscle or TRAM flap) or the back (latissimus dorsi flap), to rebuild the breast mound. This technique offers a more natural feel and appearance, with the added benefit of potential simultaneous body contouring. Guidelines provide recommendations for patient selection, preoperative evaluation, and the surgical technique for autologous tissue reconstruction.

Combining techniques, known as hybrid reconstruction, allows for the advantages of both implant-based and autologous tissue reconstruction. This approach may be beneficial for patients who require additional volume or desire a more natural appearance. The guidelines provide guidance on patient selection, surgical planning, and the optimal timing for hybrid reconstruction.

Postoperative care and surveillance are essential components of breast reconstruction guidelines. Close monitoring for potential complications, such as infection, seroma, hematoma, or implant-related issues, is crucial for timely intervention and optimal outcomes. Regular follow-up visits with the surgical team and multidisciplinary collaboration ensure comprehensive care and address any concerns that may arise during the recovery process.

The impact of breast reconstruction on survival rates in breast cancer is a topic of ongoing research. While breast reconstruction itself does not directly affect the risk of cancer recurrence or survival, it plays a crucial role in improving the overall well-being and psychosocial outcomes of breast cancer survivors. By addressing the emotional and physical consequences of breast loss, reconstruction contributes to a better quality of life, reduced psychological distress, and improved adherence to adjuvant therapies.

In conclusion, breast reconstruction guidelines provide evidence-based recommendations and standardized approaches for optimizing patient care and increasing survival rates in breast cancer. Breast reconstruction plays a vital role in improving the psychological well-being and quality of life of breast cancer survivors. The choice of reconstruction technique is based on patient preferences, individual characteristics, and the expertise of the surgical team. Regular postoperative care and surveillance are essential for managing potential complications and ensuring optimal outcomes. Ongoing research continues to explore the impact of breast reconstruction on survival rates and further refine guidelines to provide the best possible care for breast cancer patients undergoing reconstruction.

Discussion

Breast cancer is a complex disease that requires a multidisciplinary approach for effective management. Surgery plays a crucial role in the treatment of breast cancer, and evidence-based guidelines have been developed to provide healthcare professionals with standardized recommendations for surgical interventions aimed at increasing survival rates [3-5]. These guidelines encompass various aspects of breast cancer surgery, including the selection of appropriate surgical procedures, timing of

surgery, and the importance of achieving clear surgical margins.

One of the primary goals of breast cancer surgery is to remove the tumor, along with any surrounding cancerous tissue, while preserving the cosmetic appearance of the breast as much as possible. The guidelines emphasize the importance of achieving clear surgical margins, which refers to the absence of cancer cells at the edges of the excised tissue. Clear margins are associated with a decreased risk of local recurrence and improved survival rates. The recommended margin width may vary depending on the tumor characteristics and individual patient factors, and it is generally determined through a collaborative decision-making process involving the surgeon, pathologist, and oncology team [9].

Breast-conserving surgery, also known as lumpectomy or partial mastectomy, involves the removal of the tumor along with a surrounding margin of healthy tissue. This approach aims to preserve the breast and is typically followed by radiation therapy to reduce the risk of local recurrence. The guidelines provide recommendations for patient selection, appropriate tumor size, and the need for oncoplastic techniques to optimize cosmetic outcomes while ensuring complete tumor removal. Adherence to these guidelines has been shown to achieve similar survival rates compared to mastectomy while allowing for breast preservation [19].

Mastectomy involves the complete removal of the breast tissue and may be recommended in certain situations, such as large tumors, multifocal disease, or patient preference. Guidelines emphasize the importance of thorough preoperative evaluation, including breast imaging, to accurately assess tumor size, multifocality, and the potential need for neoadjuvant therapy. Additionally, guidelines provide recommendations for the optimal timing of mastectomy, taking into account

factors such as the tumor's response to neoadjuvant therapy, patient preferences, and the need for immediate breast reconstruction. Immediate breast reconstruction following mastectomy has been shown to positively impact patient outcomes, including psychosocial well-being and quality of life [22].

Sentinel lymph node biopsy (SLNB) is a vital component of breast cancer surgery for accurate staging and the determination of appropriate adjuvant therapies. SLNB involves the identification and removal of the first lymph nodes to which cancer cells are most likely to spread. The guidelines emphasize the importance of SLNB in accurately staging the axilla while minimizing morbidity associated with complete axillary lymph node dissection (ALND). SLNB has been shown to have similar survival rates compared to ALND, with fewer complications and improved quality of life. However, in cases where sentinel lymph nodes are found to be positive for cancer cells, ALND may be considered to remove additional lymph nodes and reduce the risk of disease recurrence. The guidelines also address the importance of multidisciplinary collaboration in breast cancer surgery. A multidisciplinary approach involving surgeons, oncologists, pathologists, radiologists, and other healthcare professionals ensures comprehensive evaluation, treatment planning, and follow-up care. Regular tumor board meetings and discussions facilitate the exchange of expertise and knowledge, leading to more informed decision-making based on the latest evidence and guidelines.

In addition to the surgical management of the primary tumor, guidelines emphasize the importance of systemic therapies, such as chemotherapy, hormonal therapy, and targeted therapy, in improving survival rates in breast cancer patients. The integration of surgical interventions with these adjuvant therapies is crucial for optimal treatment outcomes. The guidelines provide recommendations for the

appropriate sequencing and timing of surgical interventions and systemic therapies to maximize survival rates and minimize treatment-related complications.

Ongoing research and advancements in surgical techniques, imaging modalities, and molecular profiling continue to refine breast cancer surgery guidelines. Innovations in techniques such as oncoplastic surgery, nipple-sparing mastectomy, and intraoperative imaging contribute to improved cosmetic outcomes and reduced morbidity. Molecular profiling techniques, such as gene expression profiling and next-generation sequencing, provide valuable information about tumor biology and can help guide treatment decisions, including the selection of adjuvant therapies [48].

Conclusion

In conclusion, breast cancer surgery guidelines play a crucial role in optimizing patient care and increasing survival rates. These guidelines encompass various aspects of surgical management, including achieving clear surgical margins, breast-conserving surgery, mastectomy, sentinel lymph node biopsy, and multidisciplinary collaboration. Adherence to these guidelines ensures comprehensive evaluation, treatment planning, and follow-up care, leading to improved outcomes for breast cancer patients. Ongoing research and advancements in surgical techniques and molecular profiling continue to refine these guidelines, further enhancing the effectiveness of breast cancer surgery and overall patient survival rates.

References

- [1] A Afshari, et al. *Advances in Materials Science and Engineering*. **2022**;2022:6491134. [[Crossref](#)], [[Google Scholar](#)], [[Publisher](#)]
- [2] A Susanabadi, et al., *Journal of Chemical Reviews*, **2021**, 3 (3), 219-231, [[Crossref](#)], [[Google Scholar](#)], [[Publisher](#)]

- [3] AR Baghestani, P Shahmirzalou, S Sayad, ME Akbari, F Zayeri, Asian Pacific journal of cancer prevention: APJCP, **2018** 19 (6), 1601 [[Crossref](#)], [[Google Scholar](#)], [[Publisher](#)]
- [4] D Aghamohamadi., M.K. Gol., Int J Womens Health Reprod Sci, **2020**. 8(2): p. 227-31. [[Google Scholar](#)], [[Publisher](#)]
- [5] D Alvandfar., M. Alizadeh, M. Khanbabayi Gol, The Iranian Journal of Obstetrics, Gynecology and Infertility, **2019**. 22(9): p. 1-7. [[Crossref](#)], [[Google Scholar](#)], [[Publisher](#)]
- [6] E Tahmasebi, M Alam, M Yazdani, H Tebyanian, A Yazdani, A Seifalian, et al. Journal of Materials Research and Technology. **2020**;9(5):11731-55. [[Crossref](#)], [[Google Scholar](#)], [[Publisher](#)]
- [7] E Tahmasebi, M Alam, M Yazdani, H Tebyanian, A Yazdani, A Seifalian, et al. Journal of Materials Research and Technology. **2020**;9(5):11731-55. [[Crossref](#)], [[Google Scholar](#)], [[Publisher](#)]
- [8] E Yahaghi, F Khamesipour, F Mashayekhi, F Safarpour Dehkordi, MH Sakhaei, M Masoudimanesh, MK Khameneie. BioMed Research International. **2014** 12;2014: 757941. [[Crossref](#)], [[Google Scholar](#)], [[Publisher](#)]
- [9] M Bonyadi, Esmaeili M, Abhari M, Lotfi A. Genetic testing and molecular biomarkers. **2009**, 13: 689-92. [[Crossref](#)], [[Google Scholar](#)], [[Publisher](#)]
- [10] M Eidy, Ansari M, Hosseinzadeh H, Kolahdouzan K. Pakistan Journal of Medical Sciences. **2010**; 26(4):778-781. [[Google Scholar](#)], [[Publisher](#)]
- [11] R Azhough R, Azari Y, Taher S, Jalali P. Asian Journal of Endoscopic Surgery. **2021**;14(3):458-63. [[Crossref](#)], [[Google Scholar](#)], [[Publisher](#)]
- [12] R Azhough, R., Jalali, P., E J Golzari, S. et al. Indian J Surg. **2020**; **82**:824-827. [[Crossref](#)], [[Google Scholar](#)], [[Publisher](#)]
- [13] SM Ronagh, PANAHALI A, LOTFI A, Ahmadpour PF. Razi Journal of Medical Science. **2018**. [[Google Scholar](#)], [[Publisher](#)]
- [14] Eskandar S, Jalali P. Revista espanola de cardiologia (English ed.). **2020**; 74(8): 725-726. [[Crossref](#)], [[Google Scholar](#)], [[Publisher](#)]
- [15] M Eydi, Golzari SEJ, Aghamohammadi D, Kolahdouzan K, Safari S, Ostadi Z. Anesthesiology and Pain Medicine; **2014**: 4(2),e15499 [[Crossref](#)], [[Google Scholar](#)], [[Publisher](#)]
- [16] F Beiranvandi, et al., Journal of Pharmaceutical Negative Results, **2022** 4417-4425 [[Crossref](#)], [[Google Scholar](#)], [[Publisher](#)]
- [17] FB SS Seyedian, A shayesteh, Elsevier, **2018** 2526-2530 [[Crossref](#)], [[Google Scholar](#)], [[Publisher](#)]
- [18] Forghani N, Jalali Z, Ayramlou H, Jalali P. J Clin Images Med Case Rep. **2022**;3(1):1626.
- [19] G Sharifi, A Jahanbakhshi, et al., Global spine journal, **2012** 2 (1), 051-055 [[Crossref](#)], [[Google Scholar](#)], [[Publisher](#)]
- [20] G Sharifi, A Jahanbakhshi, Journal of Neurological Surgery Part A: Central European Neurosurgery, **2013** 74, e145-e148 [[Crossref](#)], [[Google Scholar](#)], [[Publisher](#)]
- [21] R Gheisari, Doroodizadeh T, Estakhri F, Tadbir A, Soufdoost R, Mosaddad S. Journal of Stomatology. **2019**;72(6):269-73. [[Crossref](#)], [[Google Scholar](#)], [[Publisher](#)]
- [22] R Gheisari, Resalati F, Mahmoudi S, Golkari A, Journal of Oral and Maxillofacial Surgery. **2018**;76(8):1652.e1-e7. [[Crossref](#)], [[Google Scholar](#)], [[Publisher](#)]
- [23] R Gheisari, Resalati F, Mahmoudi S, Golkari A, Mosaddad SA. Journal of Oral and Maxillofacial Surgery. **2018**;76(8):1652.e1-e7. [[Crossref](#)], [[Google Scholar](#)], [[Publisher](#)]
- [24] Golfeshan F, Ajami S, Khalvandi Y, Mosaddad SA, Nematollahi H. Journal of Biological Research - Bollettino della Società Italiana di Biologia Sperimentale. **2020**;93(1). [[Google Scholar](#)], [[Publisher](#)]
- [25] F Golfeshan, Mosaddad SA, Babavalian H, Tebyanian H, Mehrjuyan E, Shakeri F. India Section B: Biological Sciences. **2022**;92(1):5-10. [[Google Scholar](#)], [[Publisher](#)]

- [26] F Golfeshan, Mosaddad SA, Ghaderi F., Medicine. **2021**;2021:3304543. [[Crossref](#)], [[Google Scholar](#)], [[Publisher](#)]
- [27] H Ansari lari, et al. Advances in Materials Science and Engineering. **2022**;2022:8621666. [[Google Scholar](#)], [[Publisher](#)]
- [28] H Danesh, et al., Journal of Medicinal and Chemical Sciences, **2022**, 561-570, [[Crossref](#)], [[Google Scholar](#)], [[Publisher](#)]
- [29] M Haghdoost, Mousavi S, Gol MK, Montazer M. International Journal of Women's Health and Reproduction Sciences. **2019**; 7(4): 526-30. [[Google Scholar](#)], [[Publisher](#)]
- [30] M Haghdoost, Mousavi S, Gol MK, Montazer M. International Journal of Women's Health and Reproduction Sciences. **2019**; 7(4): 526-30. [[Google Scholar](#)], [[Publisher](#)]
- [31] M Irajian, Beheshtirooy A. International Journal of Current Microbiology and Applied Sciences. **2016**;5(1): 818-825. [[Google Scholar](#)], [[Publisher](#)]
- [32] Irajian M, Faridaalae G. Iranian Journal of Emergency Medicine. **2016**;3(3): 115-118. [[Crossref](#)], [[Google Scholar](#)], [[Publisher](#)]
- [33] K Hashemzadeh., M. Dehdilani, and M.K. Gol, Crescent Journal of Medical & Biological Sciences, **2019**. 6(4). [[Google Scholar](#)], [[Publisher](#)]
- [34] Kheradjoo H, et al., Molecular Biology Reports, **2023**, 50, 4217-4224, [[Crossref](#)], [[Google Scholar](#)], [[Publisher](#)]
- [35] M Eidi, et al., Iranian Journal of Medical Sciences. **2012**; 37(3):166-172. [[Google Scholar](#)], [[Publisher](#)]
- [36] M Jalessi, A Jahanbakhshi, et al., Interdisciplinary Neurosurgery, **2015** 2 (2), 86-89 [[Crossref](#)], [[Google Scholar](#)], [[Publisher](#)]
- [37] M Khanbabaei Gol., et al., The Iranian Journal of Obstetrics, Gynecology and Infertility, **2019**. 22(5): p. 52-60. [[Crossref](#)], [[Google Scholar](#)], [[Publisher](#)]
- [38] M Khanbabayi Gol., F. Jabarzade, V. Zamanzadeh, Nurs Midwifery J, **2017**. 15(8): p. 612-9. [[Google Scholar](#)], [[Publisher](#)]
- [39] M Milanifard, Weakness and Irritability, GMJ Medicine, **2021** 5 (1), 391-395 [[Crossref](#)], [[Google Scholar](#)], [[Publisher](#)]
- [40] M Montazer., et al., Gynecology and Infertility, **2019**. 22(8): p. 10-18. [[Crossref](#)], [[Google Scholar](#)], [[Publisher](#)]
- [41] M Najafi, A Jahanbakhshi, et al., Current Oncology, **2022** 29 (5), 2995-3012 [[Crossref](#)], [[Google Scholar](#)], [[Publisher](#)]
- [42] M Yazdanian, A Rahmani, E Tahmasebi, H Tebyanian, A Yazdanian, SA Mosaddad. in Medicinal Chemistry. **2021**;21(7):899-918. [[Crossref](#)], [[Google Scholar](#)], [[Publisher](#)]
- [43] M.K Gol., A. Dorosti, and M. Montazer, Journal of education and health promotion, **2019**. 8. [[Crossref](#)], [[Google Scholar](#)], [[Publisher](#)]
- [44] Mahdavi F, Osquee HO.2020; 23(3): 34-39. [[Crossref](#)], [[Google Scholar](#)], [[Publisher](#)]
- [45] Mahmoudi H, et al., Nanomedicine Research Journal, **2022**, 7(3), 288-293, [[Crossref](#)], [[Google Scholar](#)], [[Publisher](#)]
- [46] MN Darestani, et al., Photobiomodulation, Photomedicine, and Laser Surgery. **2023**. [[Crossref](#)], [[Google Scholar](#)], [[Publisher](#)]
- [47] Mobaraki-Asl N, Ghavami Z, Gol MK. Journal of education and health promotion. **2019**;8:179.
- [48] Moharrami M, Nazari B, Anvari HM. Trauma Monthly. **2021**; 26(4):228-234. [[Crossref](#)], [[Google Scholar](#)], [[Publisher](#)]

This journal is a double-blind peer-reviewed journal covering all areas in Chemistry, Medicinal and Petroleum. EJCMPR is published quarterly (6 issues per year) online and in print. Copyright © 2022 by ASC ([Amir Samimi Company](#)) which permits unrestricted use, distribution, and reproduction in any medium, provided the original work is properly cited.